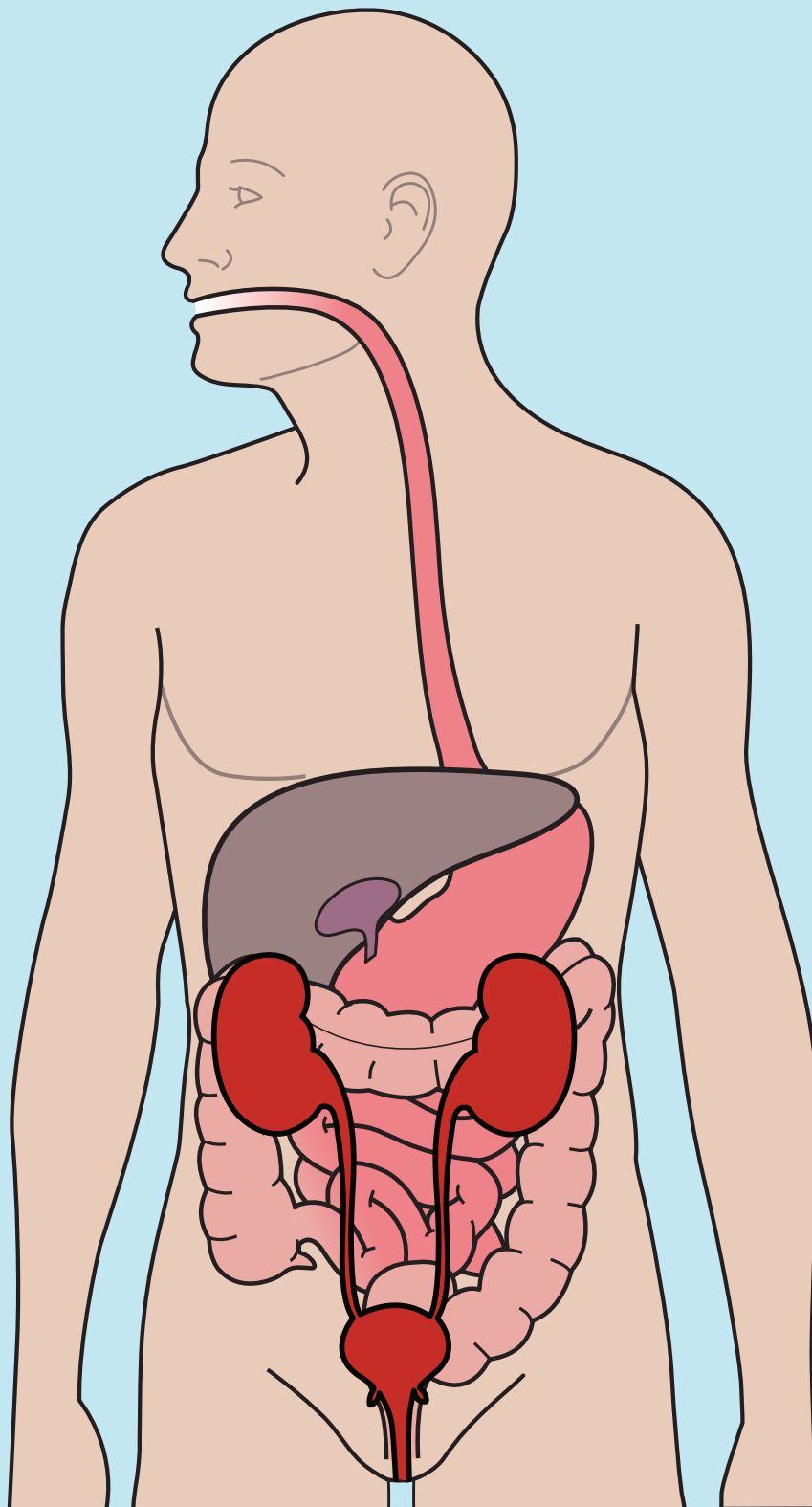


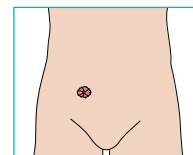
Kirurgiske procedurer ved forskellige stomityper

Pre-operative anatomi illustrationer

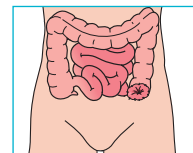


Kirurgiske procedurer ved forskellige stomityper

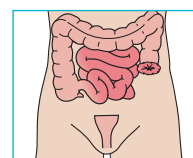
Sådan konstrueres en stomi



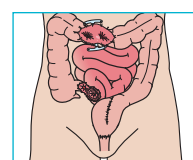
Endetarms-
amputation



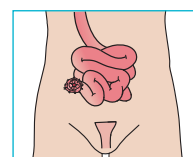
Hartmanns
operation



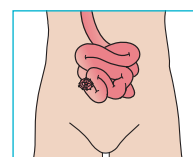
Low anterior
resection



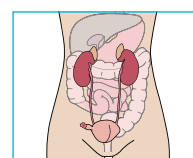
Total colectomi



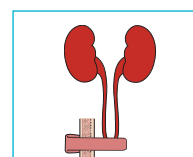
Proctocolectomi



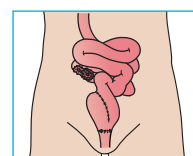
Indiana Pouch



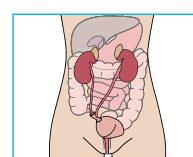
Brickerblære



Pouch



Blæresubstitution

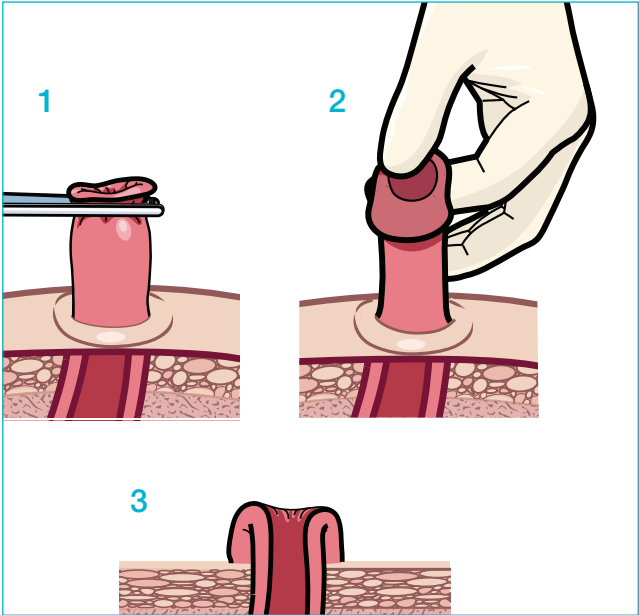


Sådan konstrueres en stomi

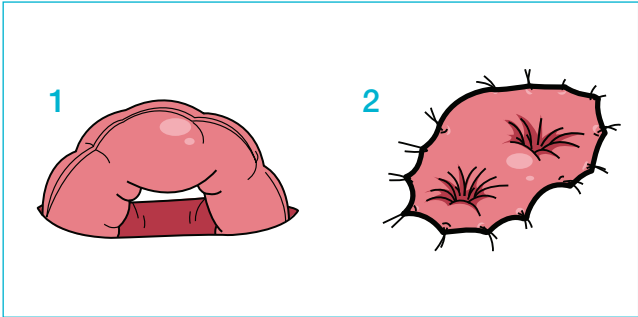
Patient data

Noter

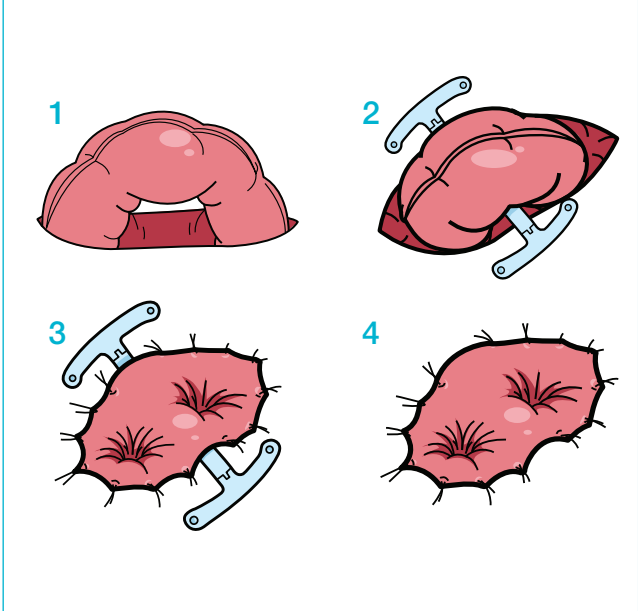
End-stomi



Loop-stomi uden stav

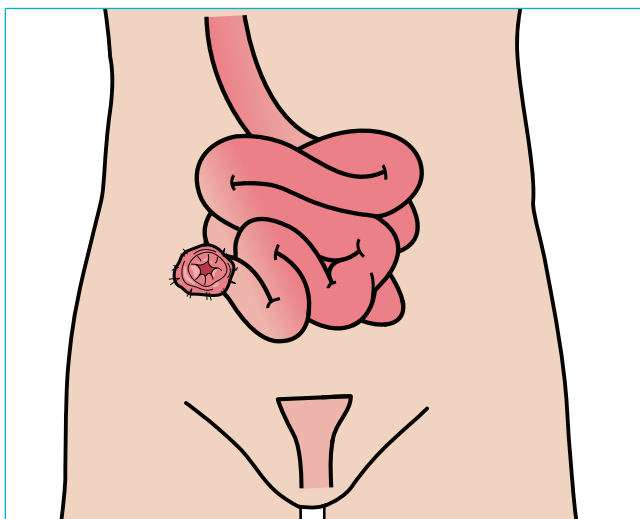


Loop-stomi med stav

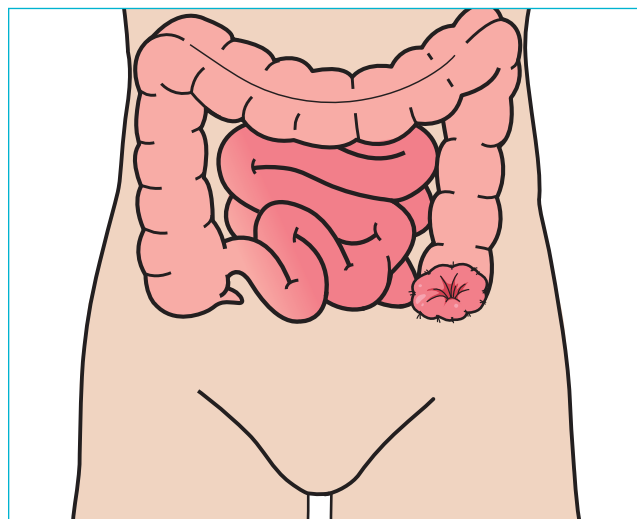


Mest almindelige stomier

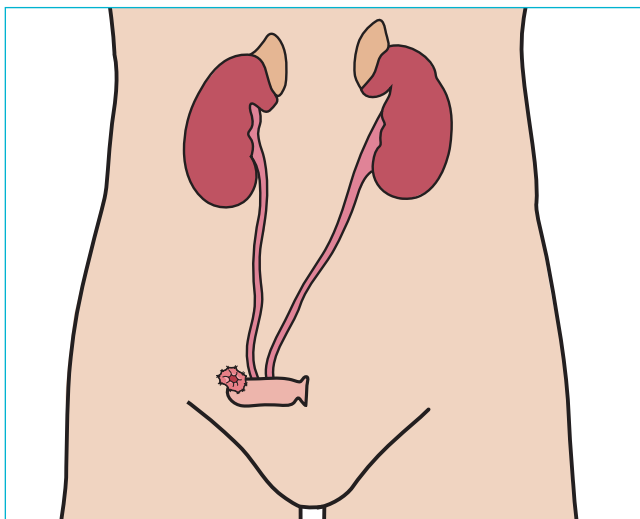
1. Ileostomi



2. Kolostomi



3. Urostomi (Brickerbære)

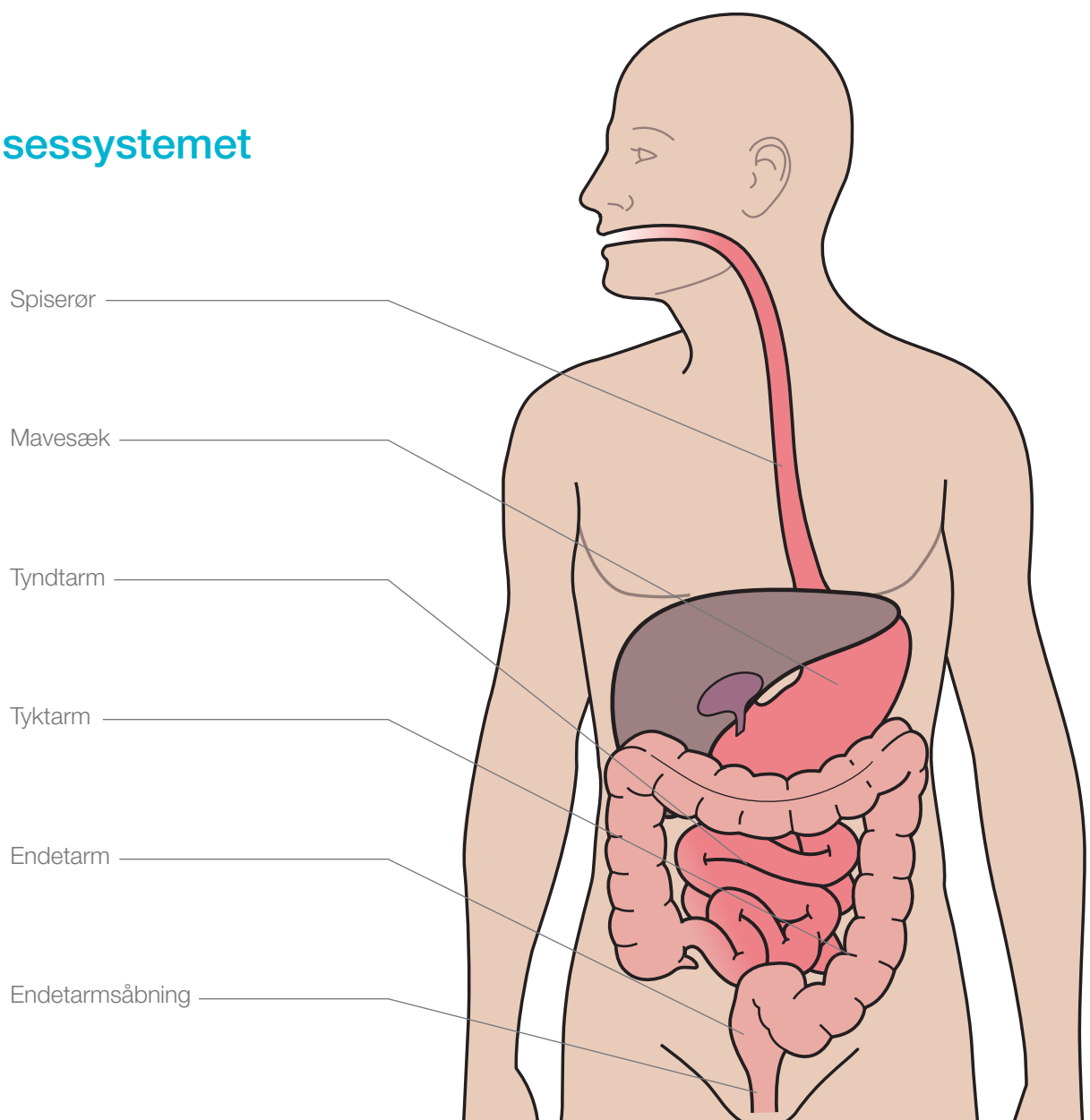


Endetarmsamputation

Patient data

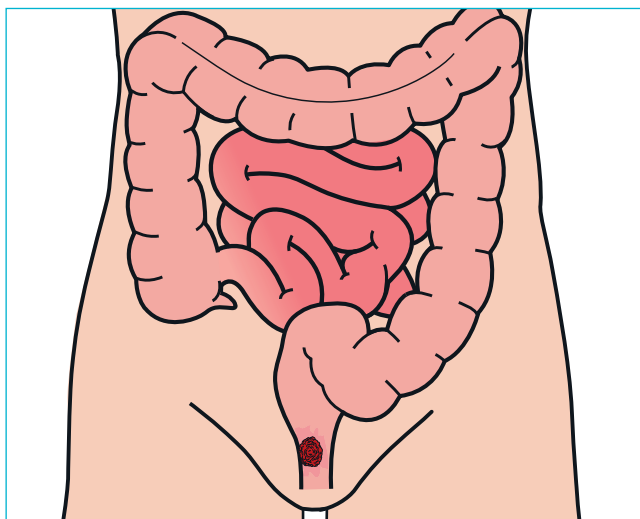
Noter

Fordøjelsessystemet

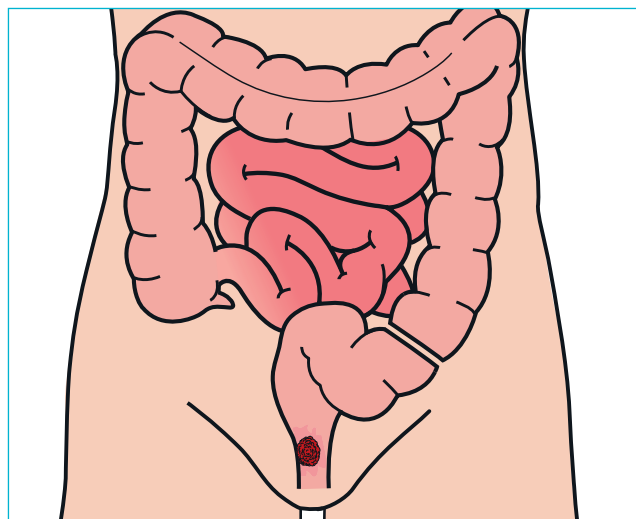


Endetarmsamputation

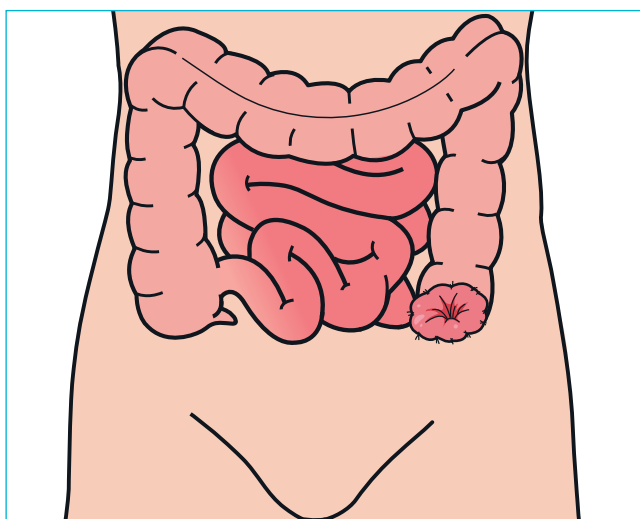
1. Cancer i endetarmen



2. Fjernelse af endetarm og endetarmsåbning



3. Kolostomi

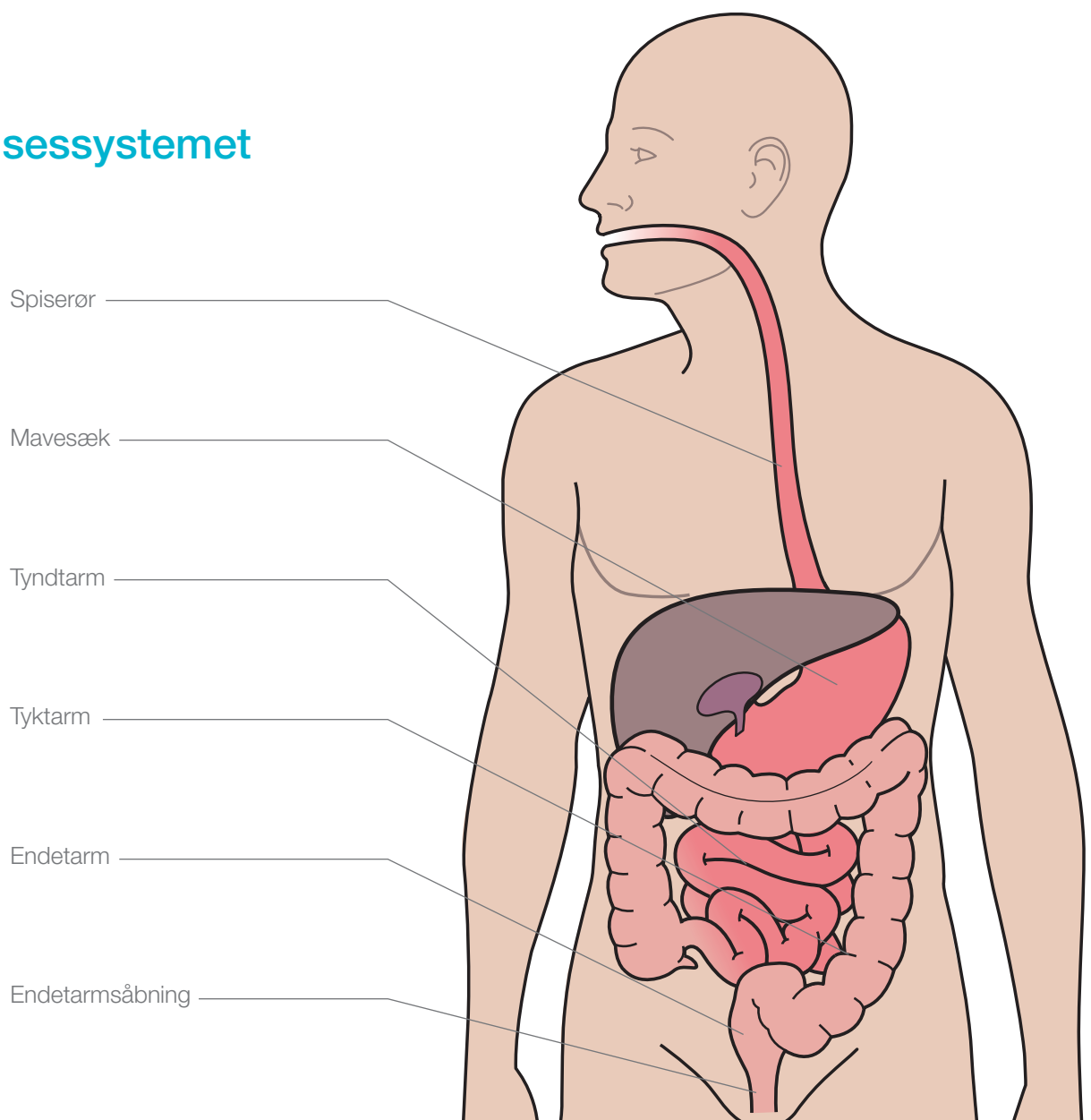


Hartmanns operation

Patient data

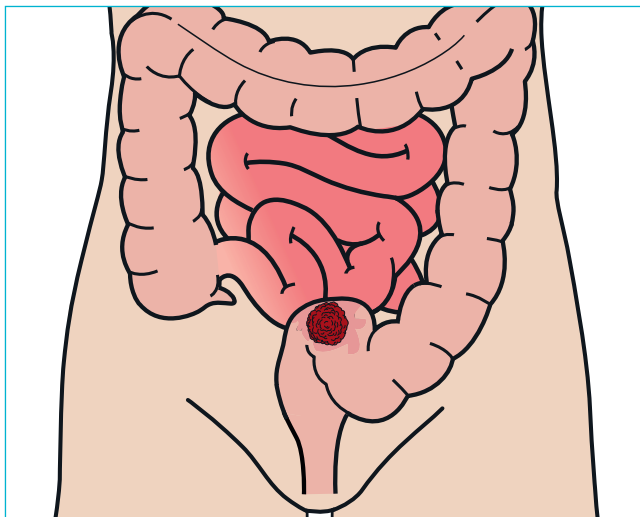
Noter

Fordøjelsessystemet

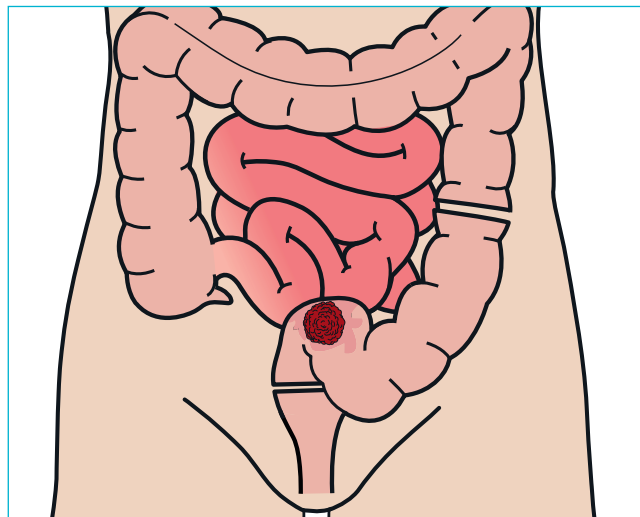


Hartmanns operation

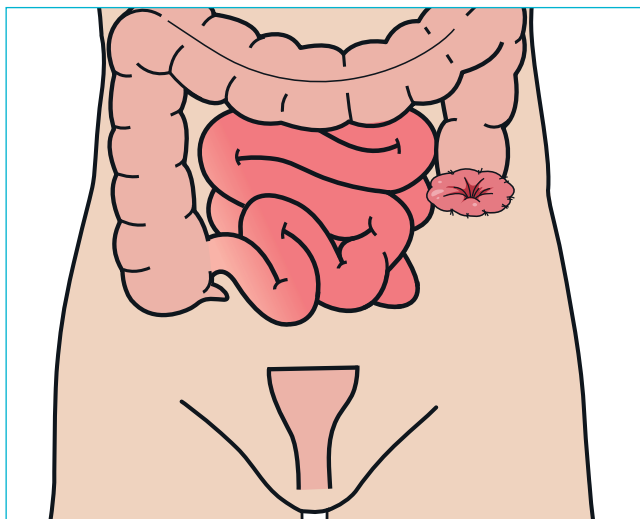
1. Cancer vækst



2. Fjernelse af tyktarm og endetarm



3. Kolostomi og ikke-fungerende tarmstykke

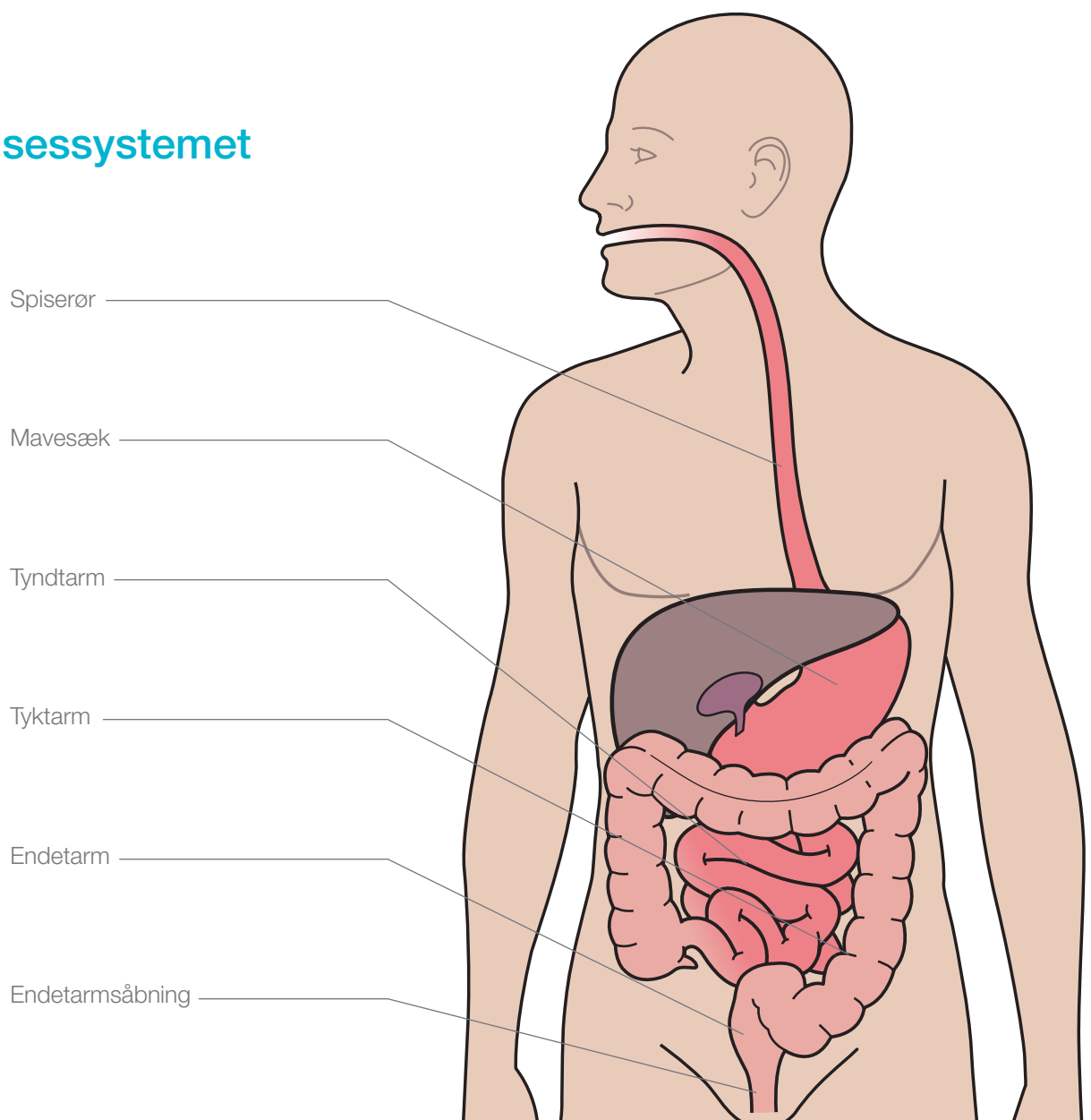


Low anterior resection

Patient data

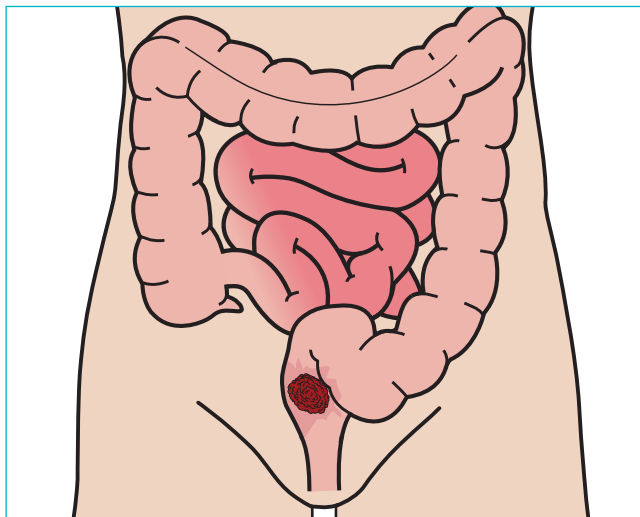
Noter

Fordøjelsessystemet

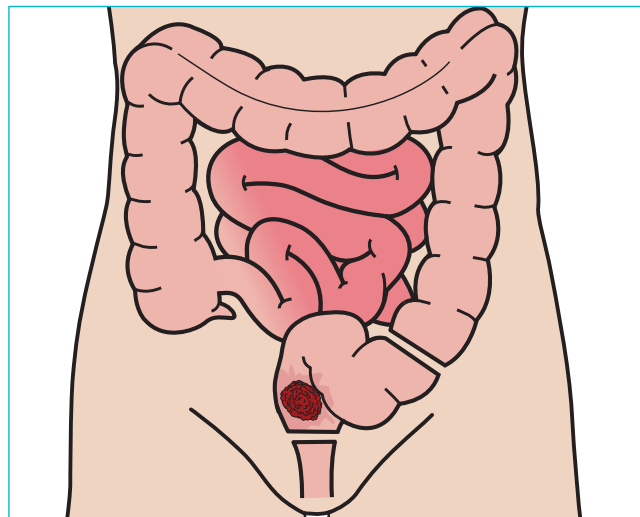


Low anterior resection

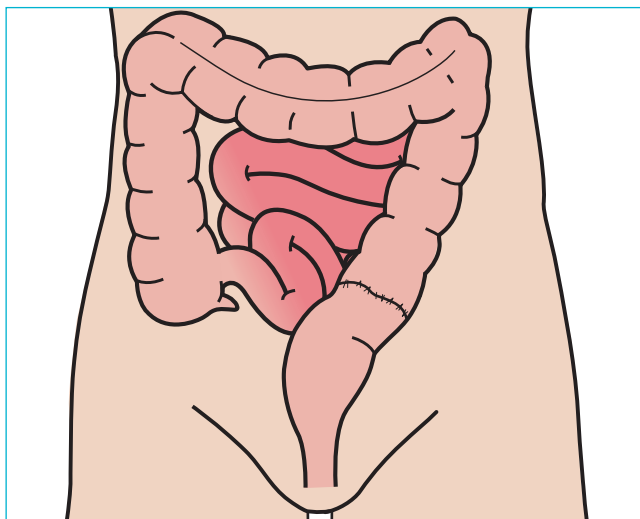
1. Cancer vækst



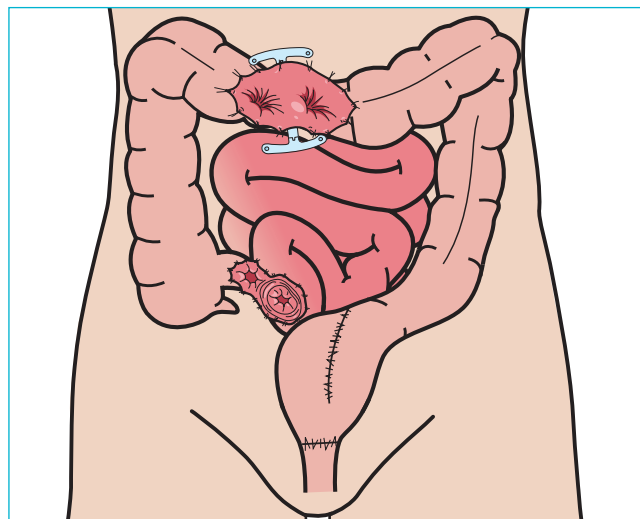
2. Endetarm fjernes



3. Tyktarm forbindes med endetarmsåbning



4. Reservoir og midlertidig loopstomi

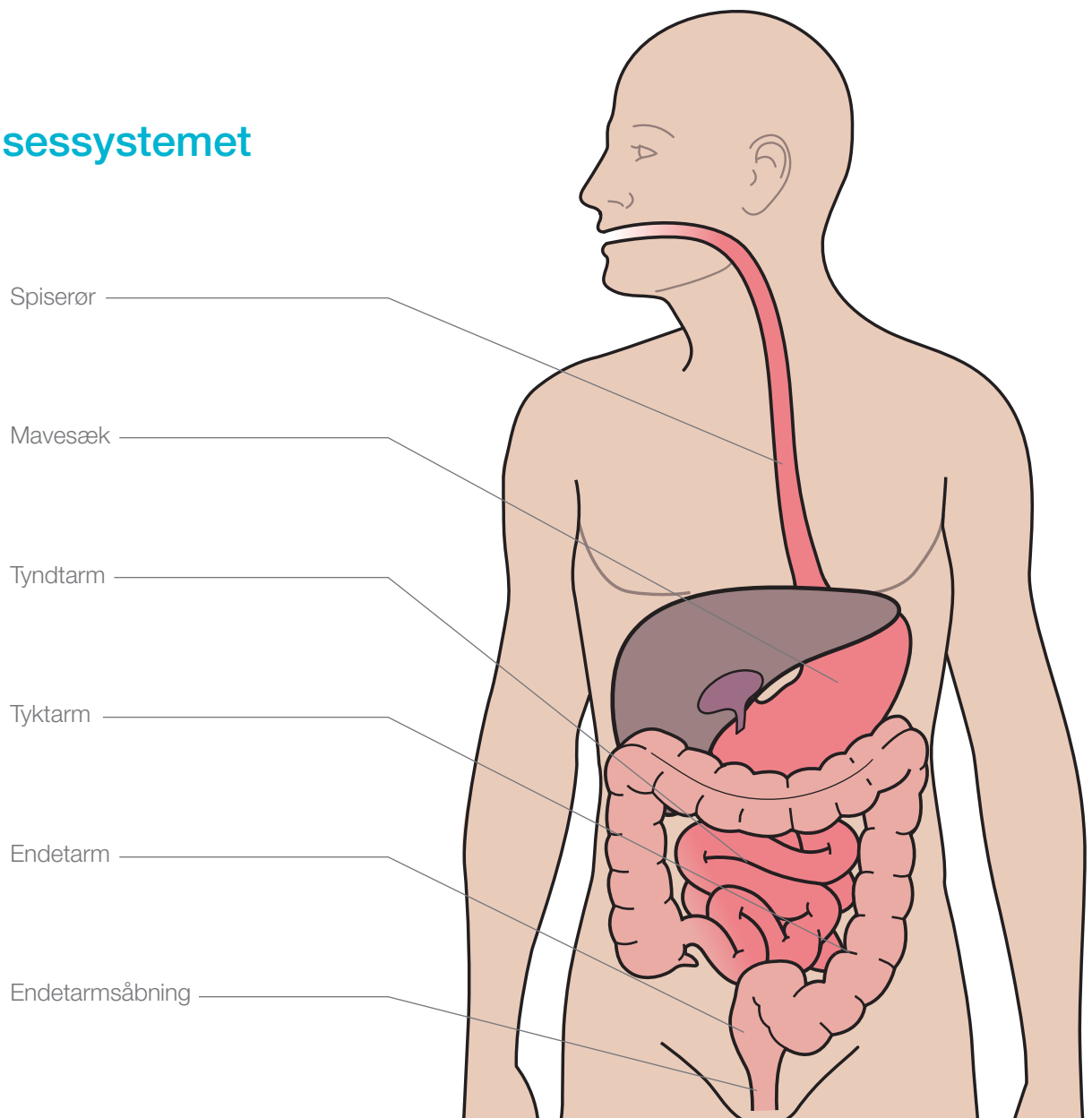


Total colectomi

Patient data

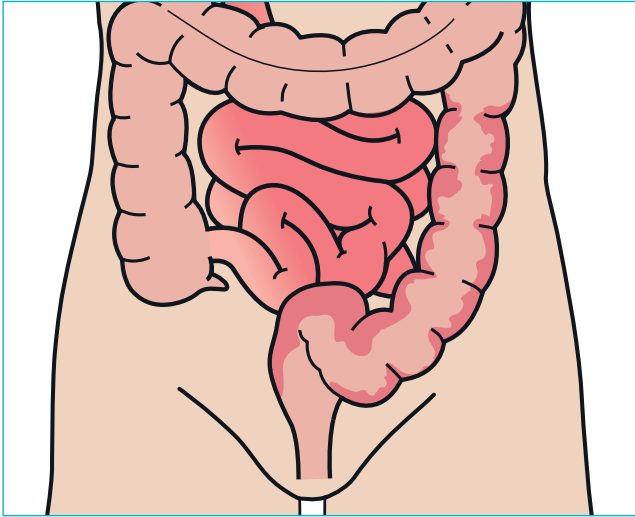
Noter

Fordøjelsessystemet

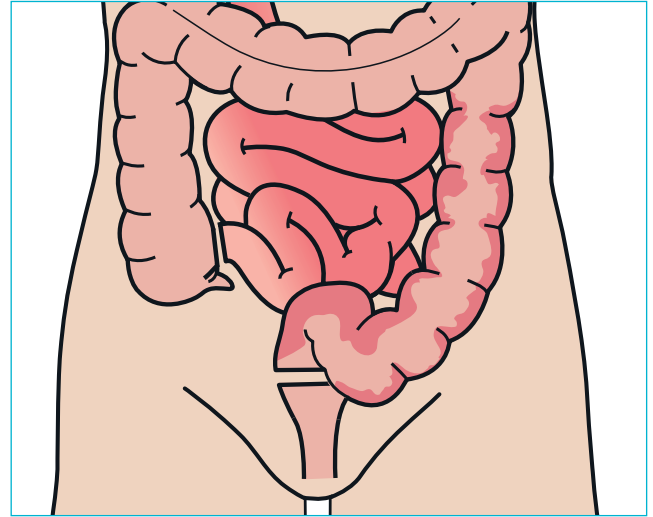


Total colectomi

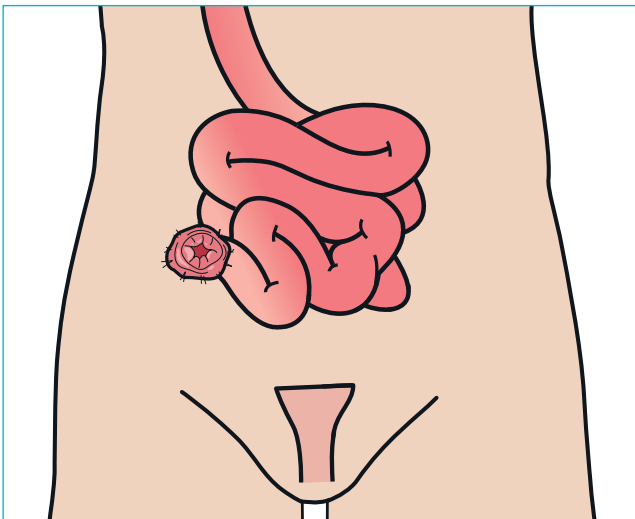
1. Syg tyktarm/endetarm



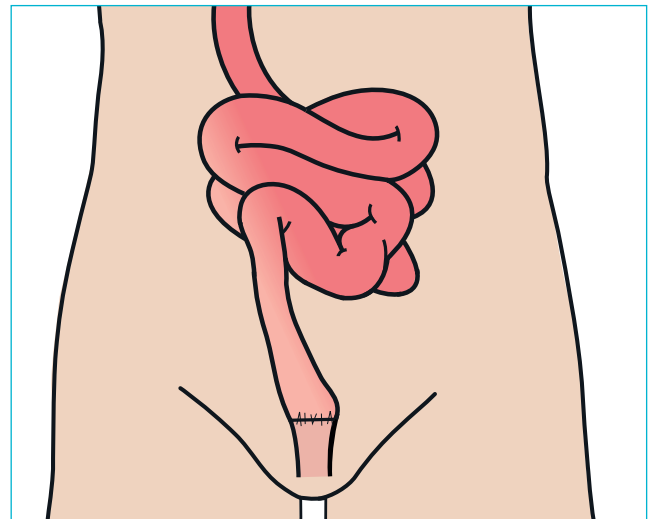
2. Tyktarm fjernes



3. Ileostomi og ikke-fungerende tarmstykke



4. Tyndtarm forbindes med endetarmsåbning

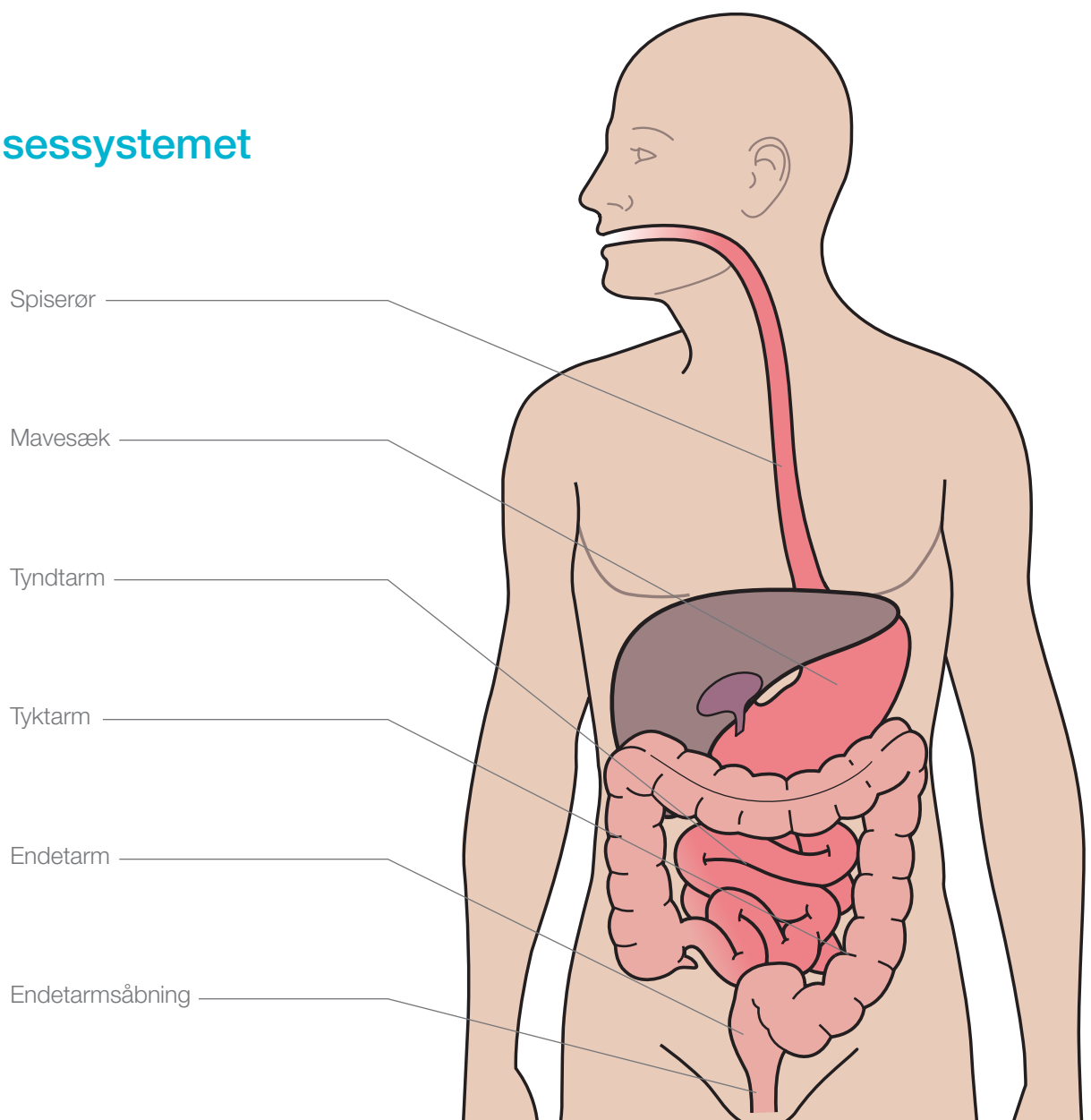


Proctocolectomi

Patient data

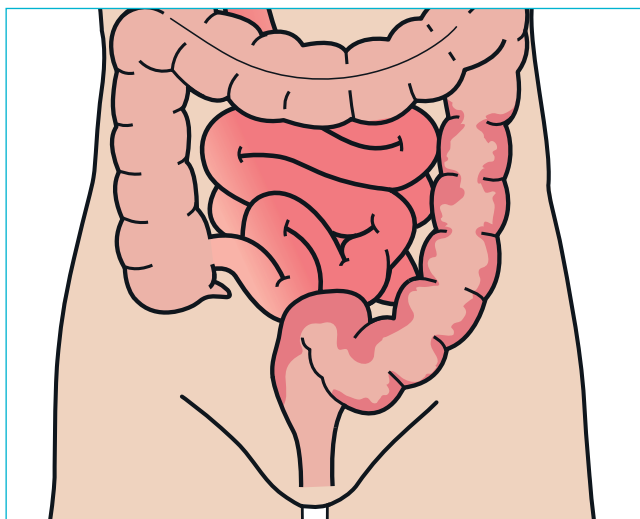
Noter

Fordøjelsessystemet

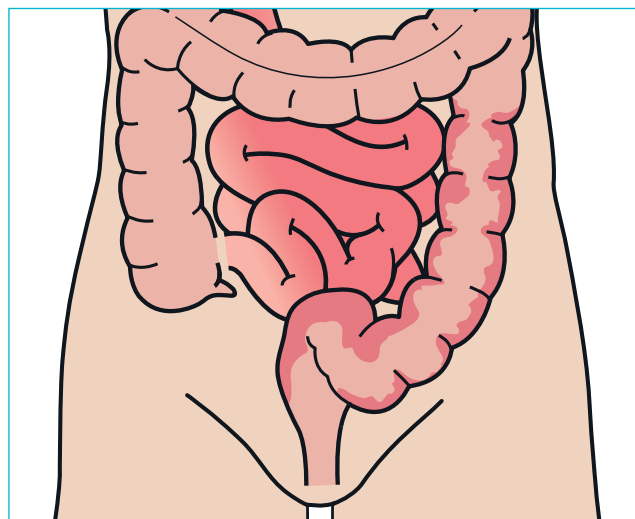


Proctocolectomi

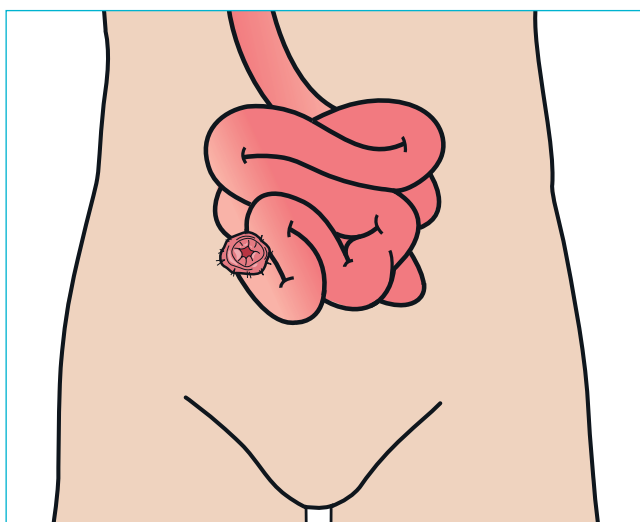
1. Syg tyktarm



2. Tyktarm/endetarm/endetarmsåbning fjernes



3. Sund tyndtarm - Ileostomi

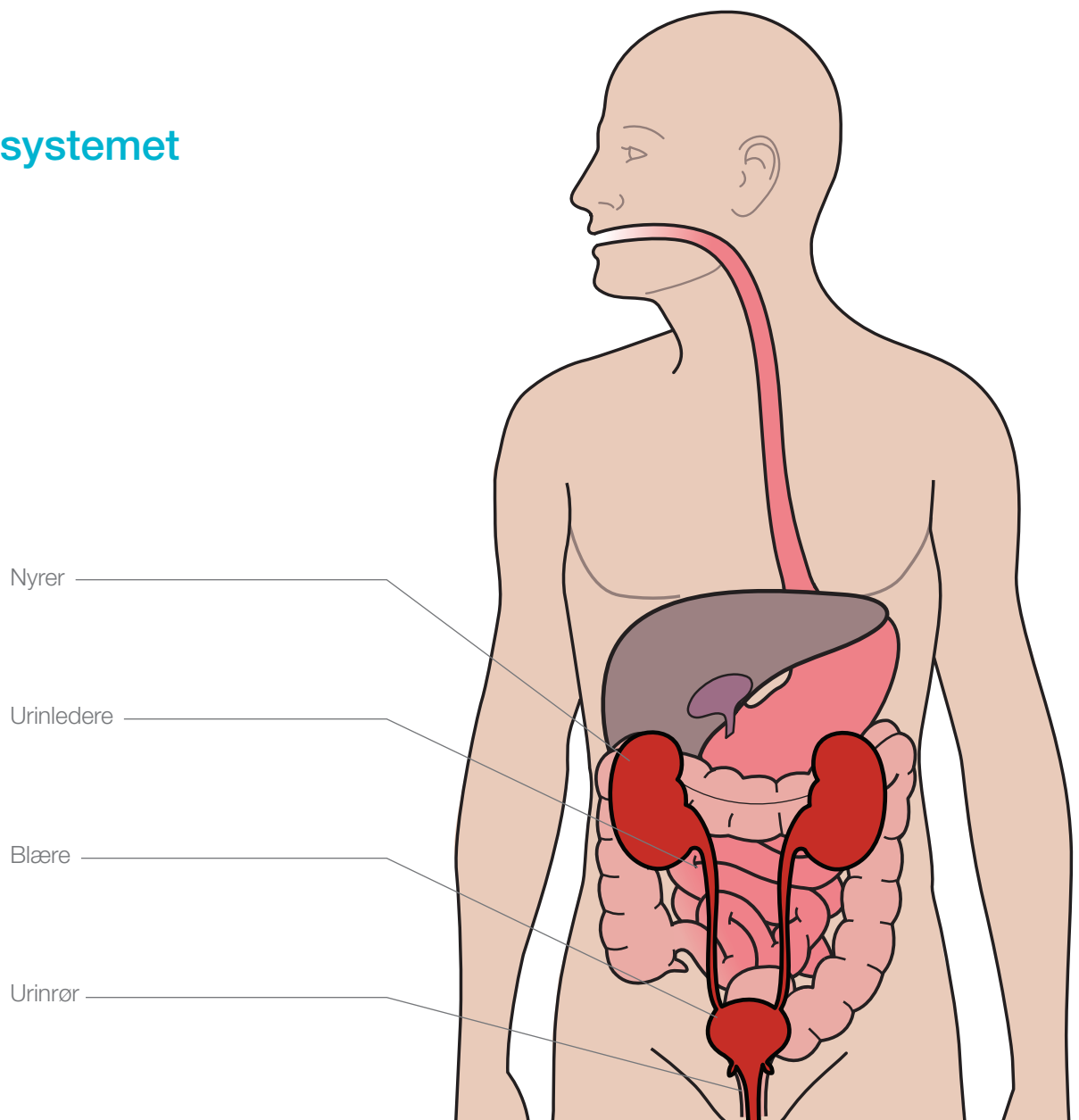


Indiana Pouch

Patient data

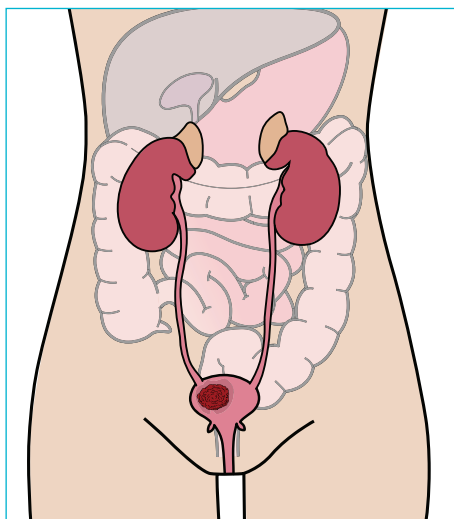
Noter

Urinvejsystemet

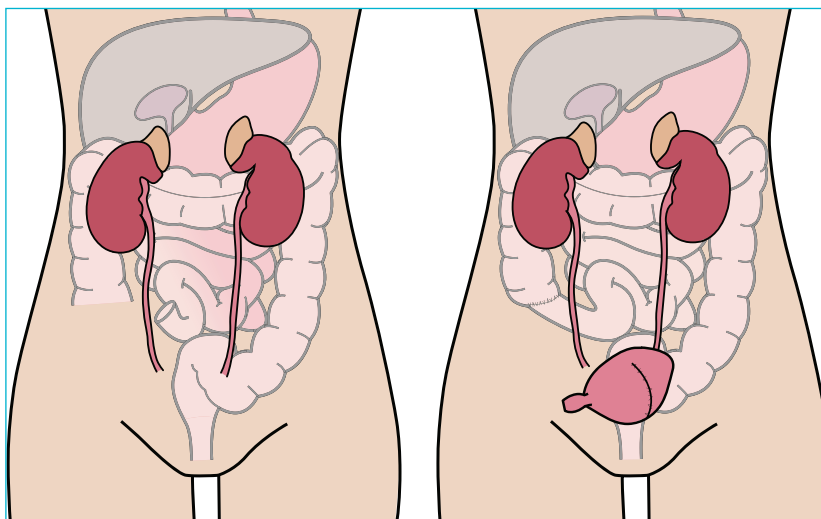


Indiana Pouch

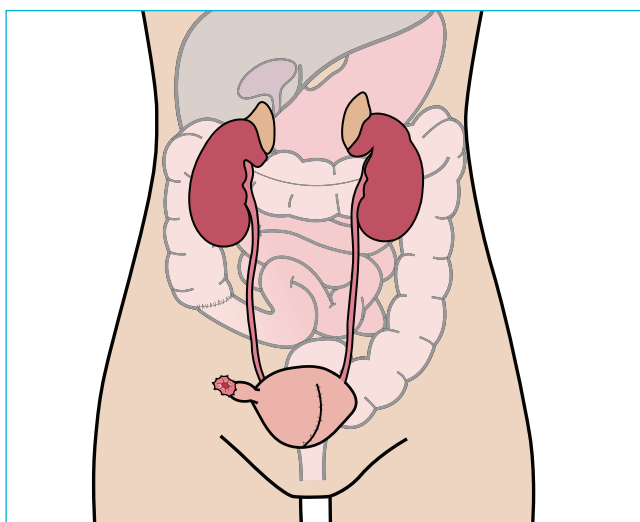
1. Syg blære



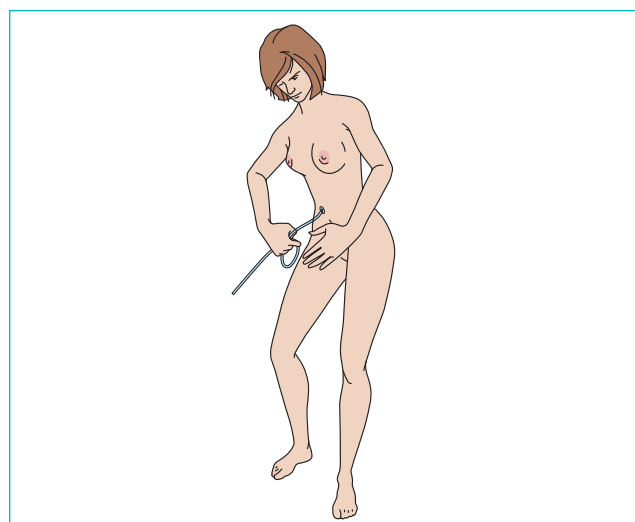
2. Blæren rekonstrueres af et stykke tyndtarm



3. Kontinent urostomi



4. Tømning af reservoir

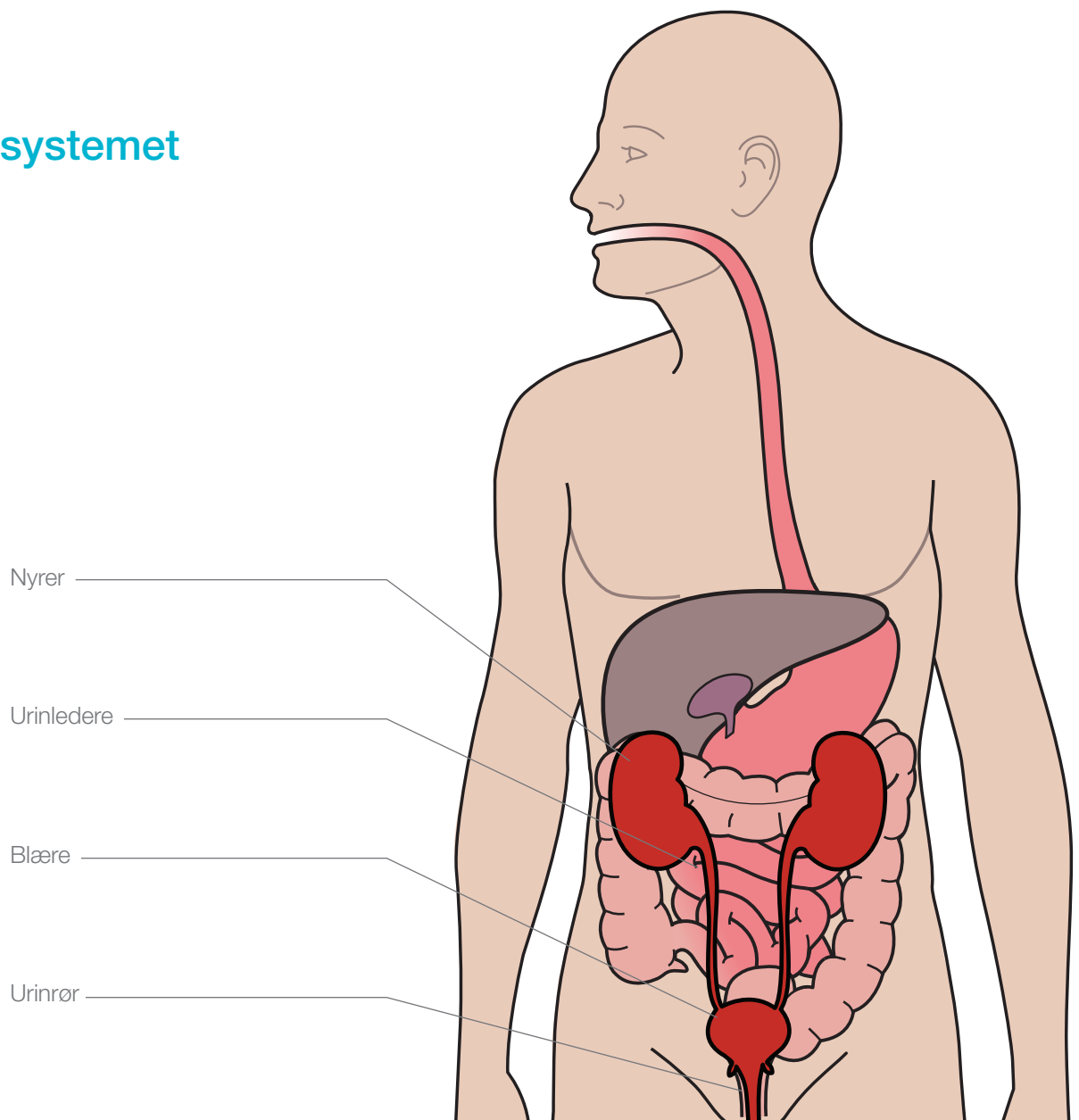


Brickerblære

Patient data

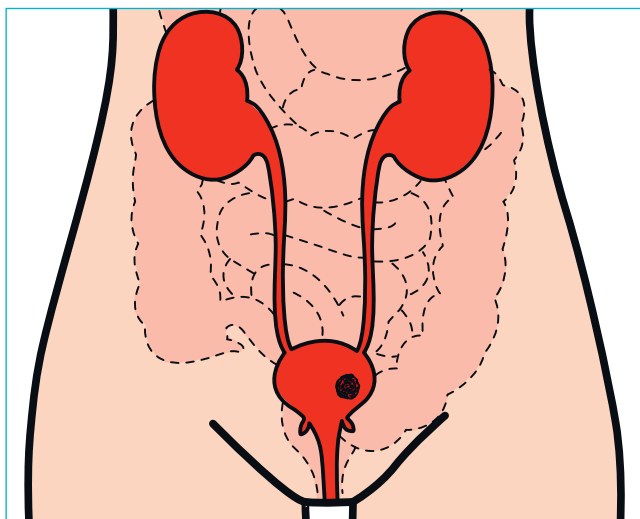
Noter

Urinvejssystemet

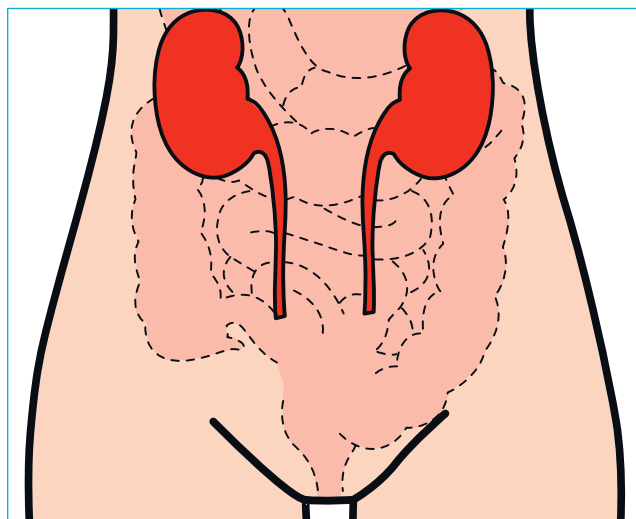


Brickerblære

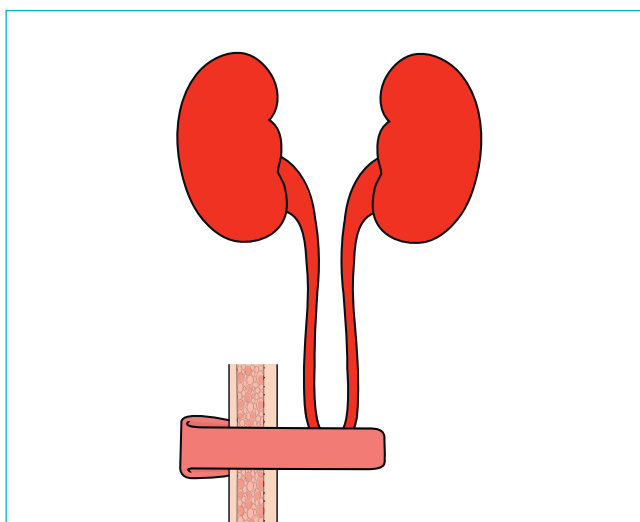
1. Syg blære



2. Blæren fjernes



3. Urostomi konstrueres

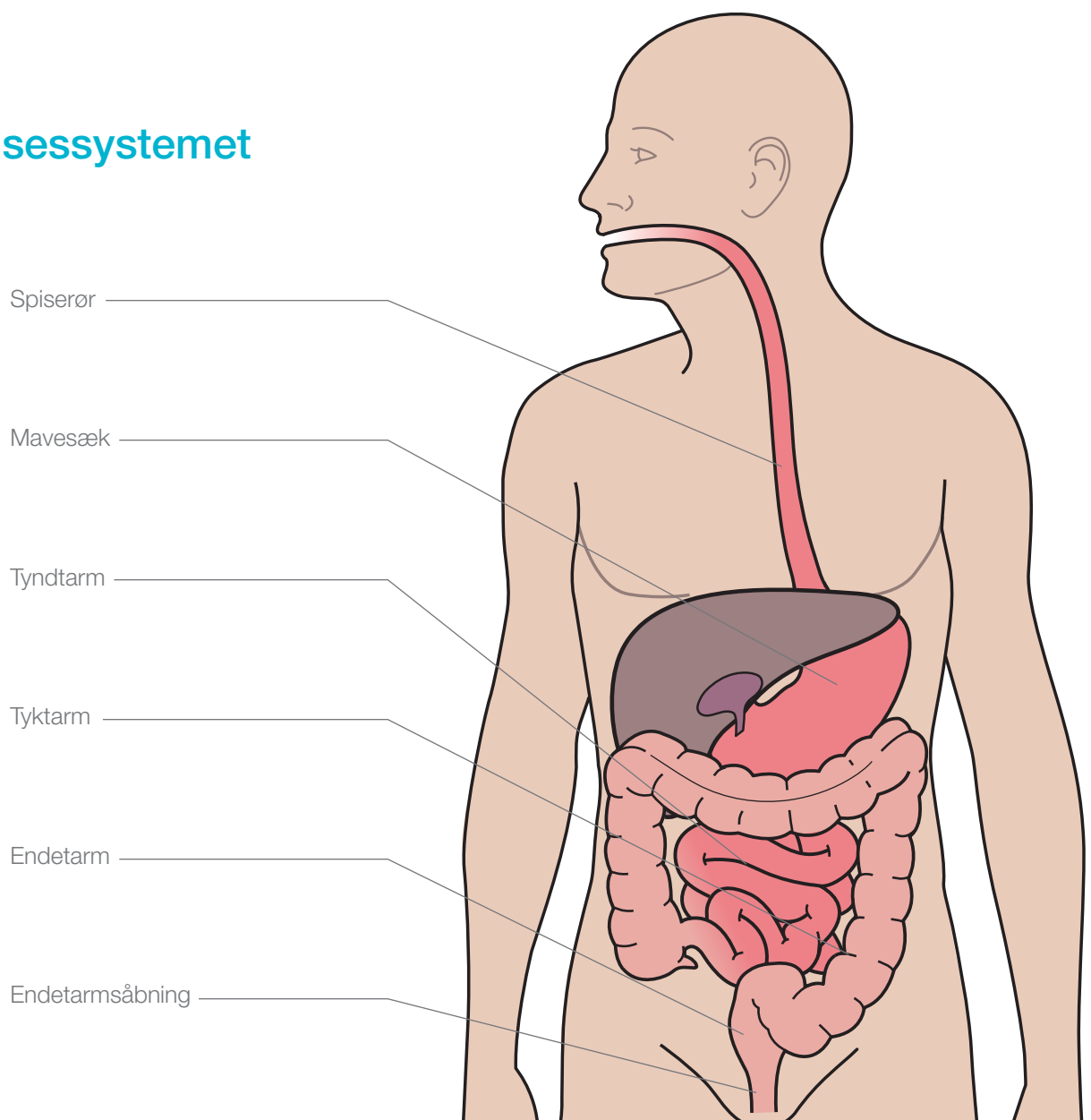


Pouch

Patient data

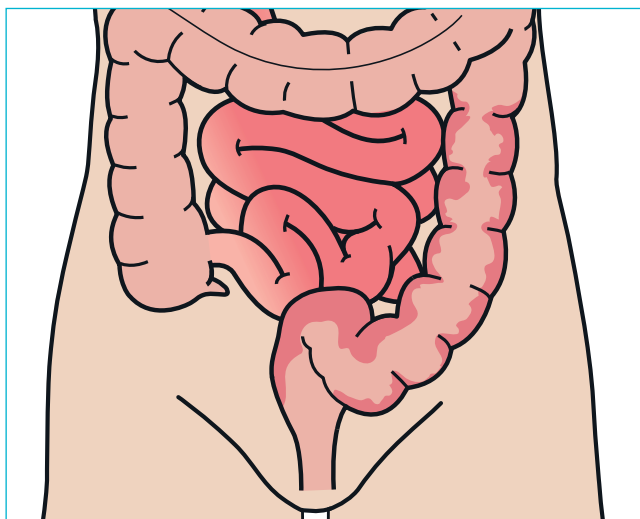
Noter

Fordøjelsessystemet

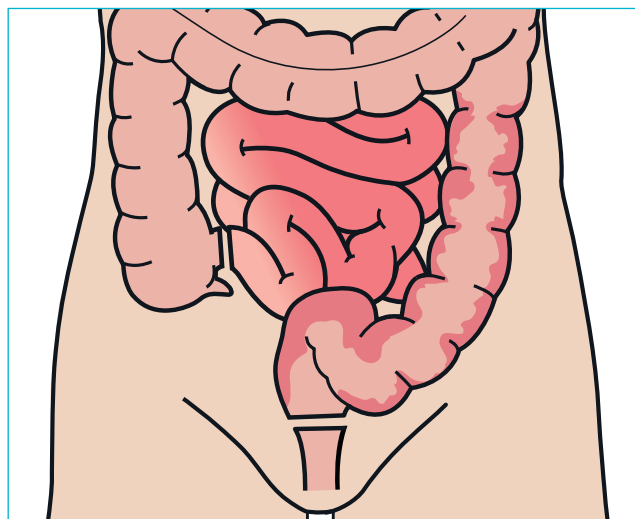


Pouch

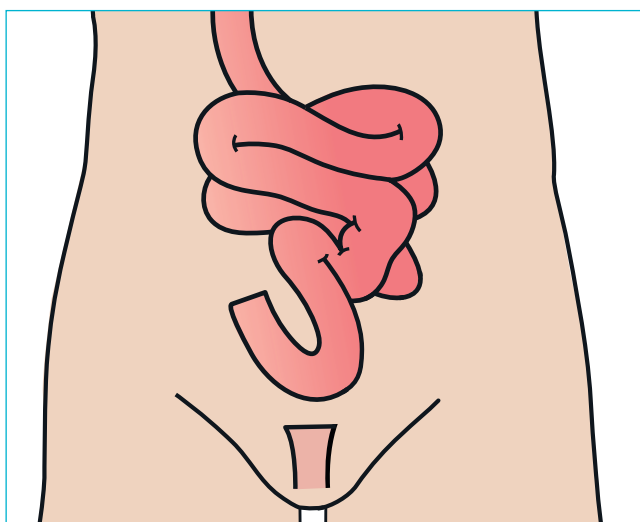
1. Syg tyktarm



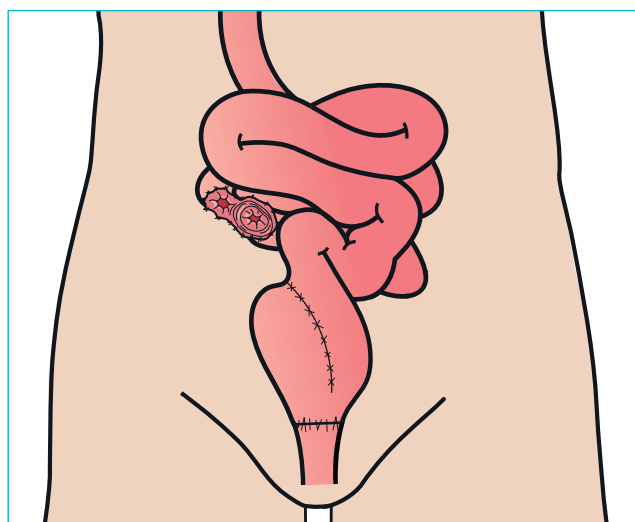
2. Tyktarm og endetarm fjernes



3. Sund tyndtarm og endetarmsåbning



4. Tyndtarm og reservoir og midlertidig ileostomi

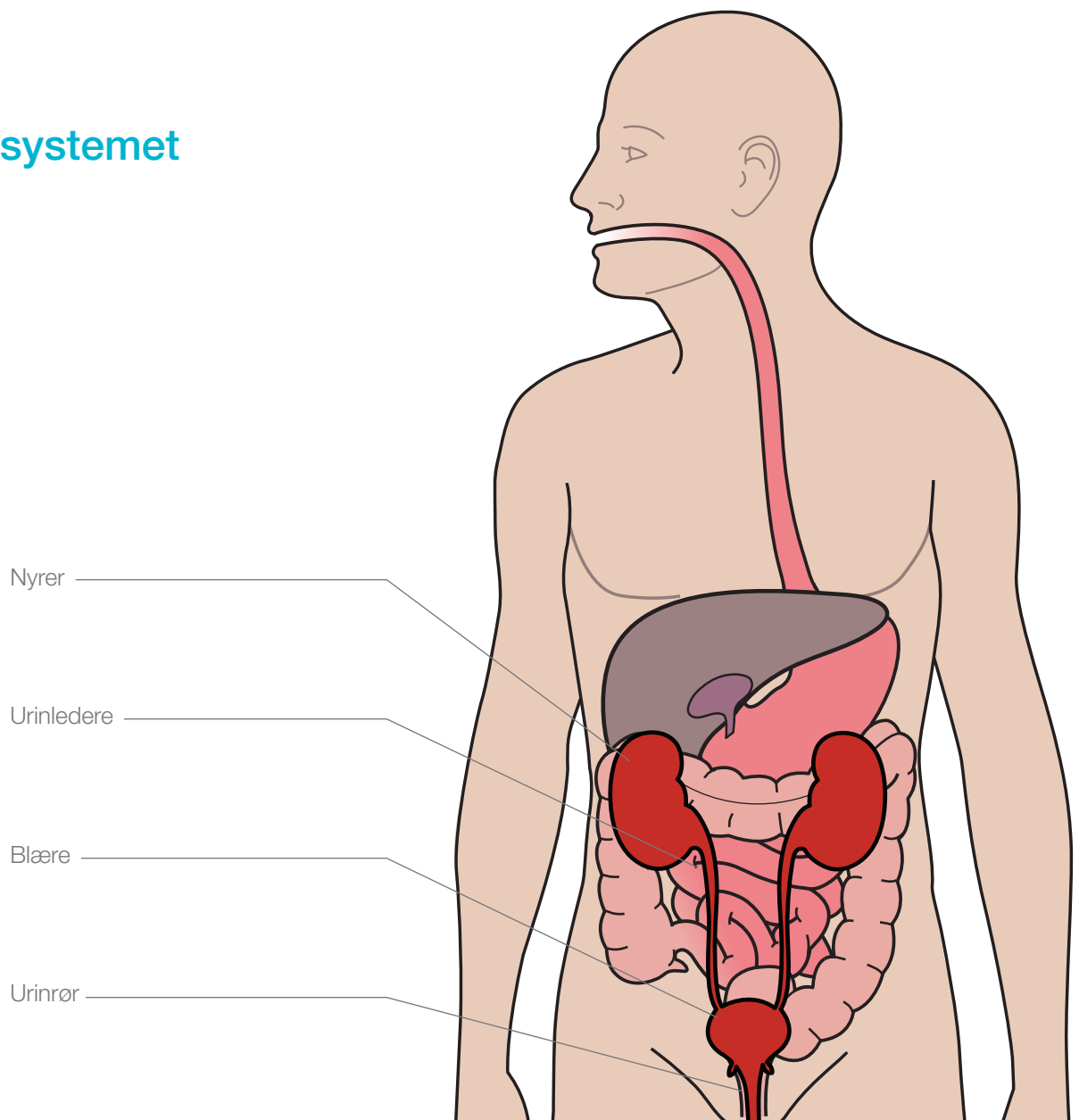


Blæresubstitution

Patient data

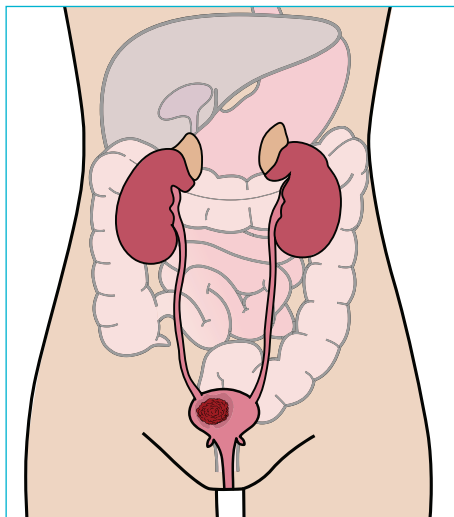
Noter

Urinvejssystemet

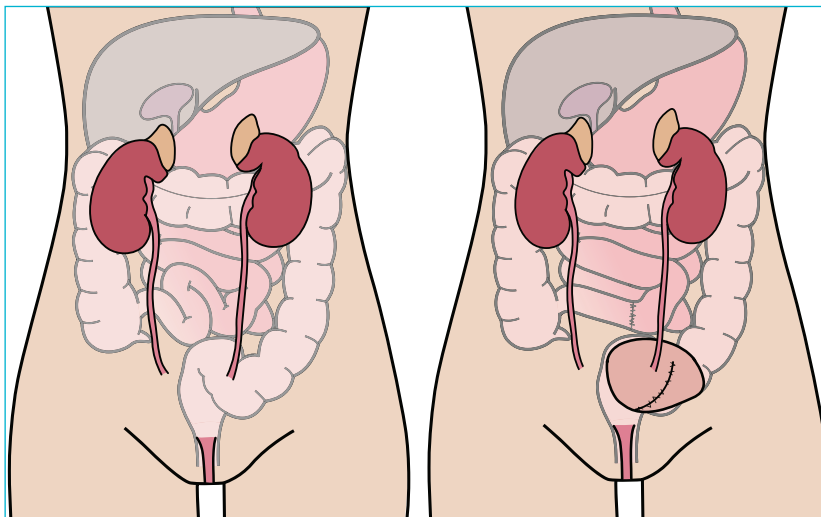


Blæresubstitution

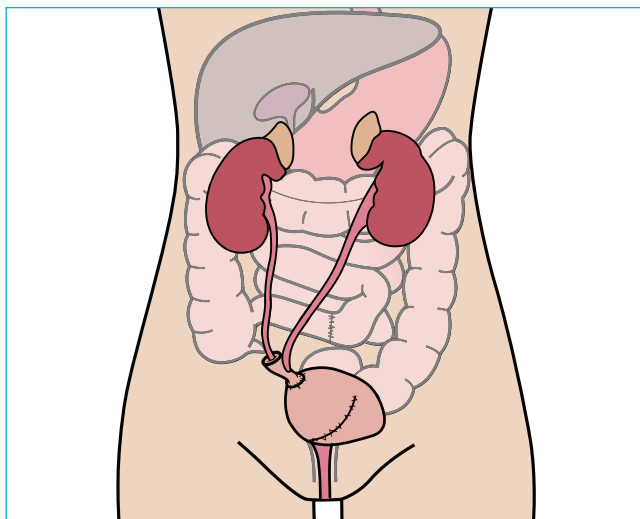
Syg blære



2. Blæren fjernes og urinrøret bevares



3. En ny blære konstrueres af et stykke tyndtarm



4. Tømning af blæren

